

Frontotemporal dementia and parkinsonism linked to chromosome 17 (FTDP-17)

Authors: Doctors Zbigniew Wszolek¹, MD, Yoshio Tsuboi, MD, Bernardino Ghetti, MD and William Cheshire, MD

Creation Date: May 2003

Scientific Editor: Doctor Thomas Gasser

¹Department of Neurology, Mayo Clinic, 4500 San Pablo Rd, FL 32224 Jacksonville Florida, United States. Wszolek.Zbigniew@mayo.edu

[Abstract](#)

[Keywords](#)

[Disease name](#)

[Excluded diseases](#)

[Diagnosis criteria / definition](#)

[Differential diagnosis](#)

[Frequency](#)

[Clinical description](#)

[Laboratory findings](#)

[Management including treatment](#)

[Etiology](#)

[Diagnostic methods](#)

[Genetic counseling](#)

[Key-words](#)

[References](#)

Abstract

Frontotemporal dementia and parkinsonism linked to chromosome 17 (FTDP-17) is an autosomal dominant neurodegenerative disorder caused by mutations in the tau gene, which encodes a microtubule-binding protein. Since the International Consensus Conference in Ann Arbor, Michigan in 1996, which defined FTDP-17, over 80 families with 31 different mutations in the tau gene have been identified. FTDP-17 is an extremely rare condition, whose prevalence and incidence remain unknown. The distribution of this disorder is worldwide including North America, Europe, Asia and Australia. Three cardinal features consisting of behavioral and personality changes, cognitive impairment, and motor symptoms characterize FTDP-17. The phenotype of FTDP-17 varies not only between families carrying different mutations but also between and within families carrying the same mutations. The pathogenetic mechanisms underlying the disorder are thought to be related to the altered proportion of tau isoforms or to the ability of tau to bind microtubules and to promote microtubule assembly. Definitive diagnosis of FTDP-17 requires a combination of characteristic clinical and pathological features and molecular genetic analysis. Currently, treatment for FTDP-17 is only symptomatic and supportive.

Keywords

frontotemporal dementia and parkinsonism linked to chromosome 17, tauopathy, genetics, tau mutations

Disease name

Frontotemporal dementia and parkinsonism linked to chromosome 17 (FTDP-17)

Excluded diseases

Other familial frontotemporal dementias, parkinson-plus syndromes, sporadic progressive supranuclear palsy (PSP), corticobasal degeneration (CBD), Pick's disease, dementia

with Lewy bodies (DLB), Parkinson's disease (PD), multiple system atrophy (MSA)

Diagnosis criteria / definition

The term frontotemporal dementia and parkinsonism linked to chromosome 17 was defined during the International Consensus Conference in Ann Arbor, Michigan in 1996 (1). At the time, affected individuals with frontotemporal dementia and parkinsonism linked to the wild locus on chromosome 17 were identified within 13 families. This syndrome is a familial disorder with autosomal dominant inheritance. The three major clinical features include behavioral disturbances, cognitive impairment, and parkinsonism. There are no strict criteria regarding the diagnosis of FTDP-17. Nevertheless, FTDP-17 should be considered in the differential diagnosis in the presence of one or more of the following (2):

- 1) Age of onset of neurological symptoms between the third and fifth decades;
- 2) Progressive neuropsychiatric syndrome including personality and behavioral abnormalities and/or frontotemporal dementia;
- 3) Parkinsonism-plus syndrome (bradykinesia, rigidity, postural instability, paucity of resting tremor, and poor or no response to dopaminergic therapy), frequently associated with falls and supranuclear gaze palsy and less commonly associated with apraxia, dystonia, and lateralization;
- 4) Progressive speech difficulties from the onset of the illness;
- 5) Seizure disorder poorly controlled with standard anticonvulsant therapy;
- 6) Positive family history suggestive of autosomal dominant inheritance of a neurodegenerative disorder, even if there has been variability in clinical presentations.

Differential diagnosis

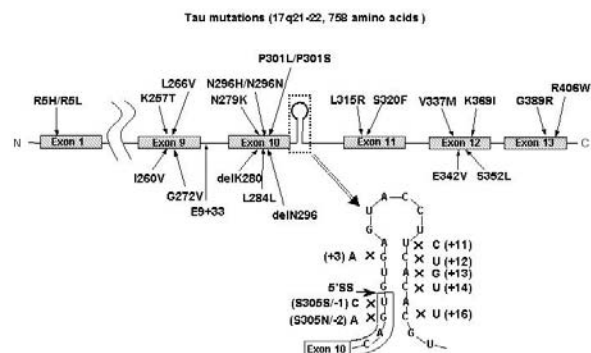
Clinically, FTDP-17 may mimic several neurodegenerative diseases. The differential diagnosis of FTDP-17 includes disorders with such initial signs as behavioral and personality abnormalities, parkinsonism, lower motor neuron dysfunction or cognitive impairments. In the absence of a positive family history or molecular genetic data, FTDP-17 is most frequently confused with Pick's disease, PSP and/or CBD. A neuropathologic examination coupled with molecular genetic analysis of the *tau* gene are essential steps toward distinguishing FTDP-17 from other neurodegenerative diseases associated with tau deposition. The pathologic analysis should include immunohistochemical studies using multiple anti-tau antibodies.

Frequency

The prevalence and incidence of FTDP-17 remain unknown. Currently over 80 families with FTDP-17 have been reported. FTDP-17 has worldwide distribution with kindreds described in USA, Great Britain, Japan, Netherlands, France, Canada, Australia, Italy, Germany, Israel, Ireland, Spain and Sweden. Some of these families share a common founder (3). FTDP-17 is an extremely rare condition. We estimate that there have been about 500-600 patients described with fewer than 50 individuals currently alive. Molecular genetic studies have identified 31 unique mutations in these families (**Figure 1**). The most common mutations are P301L, N279K and a splice site mutation (exon 10 +16), which account for approximately 60% of known cases.

Figure 1. Schematic representation of the exons and introns of the *tau* gene localized on chromosome 17.

Thirty-one identified so far mutations are presented.



Clinical description

Symptoms and signs

The onset of FTDP-17 is usually insidious. Affected individuals who have reached the fully developed stage of the disease present with a constellation of signs including at least two of the three cardinal features of FTDP-17.

- 1) Behavioral and personal disturbances,
- 2) Cognitive deficits,
- 3) Motor dysfunction (typically signs of parkinsonism-plus syndrome).

Clinical features of FTDP-17 vary considerably among affected individuals, regardless of whether they inherit the same or different mutations. Even members within a family, for example, can vary in their clinical presentation.

The specific mutations and their characteristic clinical presentations are summarized in [Table 1](#). The behavioral and personality abnormalities can include disinhibition, apathy, defective judgment, compulsive behavior, hyper-religiosity, neglect of personal hygiene, alcoholism, illicit drug addiction, verbal and physical aggressiveness, family abuse, and other manifestations. While cognitive disturbances occur, memory, orientation, and visuospatial function are relatively preserved during early stages of the disease. Progressive speech difficulties with non-fluent aphasia and disorders of executive functions can be seen initially. Subsequently, the patient develops progressive deterioration of memory, orientation, and visuospatial functions as well as echolalia, palilalia, verbal and vocal perseverations. Finally, progressive dementia and mutism occur. Motor signs are also prominent. Parkinsonism can be the first manifestation of the disease, and in this regard it is important to note that some FTDP-17 patients were initially misdiagnosed as having Parkinson's disease or PSP. In some families, however, the parkinsonism occurs late in the course of the illness or not at all. The parkinsonism in FTDP-17 is characterized by rather symmetrical bradykinesia, postural instability, rigidity affecting equally axial and appendicular musculature, usually absence of resting tremor, and poor or no responsiveness to levodopa therapy. Other motor disturbances seen in FTDP-17 include dystonia unrelated to medications, supranuclear gaze palsy, upper and lower motor neuron dysfunction, myoclonus, postural and action tremors, eyelid opening and closing apraxia, dysphagia, and dysarthria.

Phenotype-Genotype correlations

It is still very difficult to perform precise phenotype/genotype correlations in FTDP-17 since the available clinical information is not detailed enough in some families or not accessible at all. Nevertheless, some patterns have emerged. The families with FTDP-17 fall into two major groups (5):

- dementia predominant phenotype,
- parkinsonism-plus predominant phenotype.

The dementia predominant phenotype is more common and is usually seen in families with mutations in exons 1, 9, 11, 12, 13 and in exon 10 leading to a decrease in microtubule binding properties.

The parkinsonism-plus predominant phenotype is usually seen in families with intronic and exonic mutations affecting exon 10 and leading to the selective overproduction of 4R tau isoforms. These categorizations should be

viewed cautiously until more clinical and pathologic data become available.

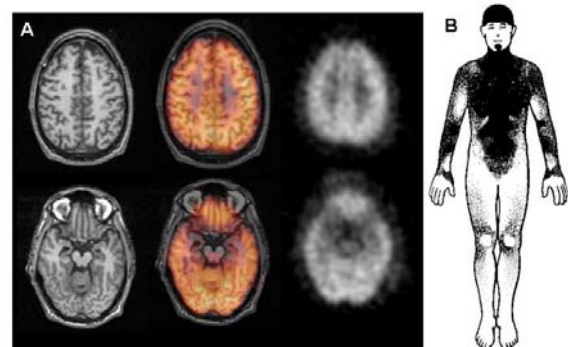
Imaging studies

Computerized tomography (CT) and magnetic resonance imaging (MRI) of the head usually demonstrate some dilation of the ventricular system and frontal, temporal, and parietal cortical atrophy (**Figure 2A**) (6-11). MRI T2-weighted images may show accumulation of paramagnetic substances (iron) in mesencephalic nuclei (8). In some kindreds, asymmetrical cortical atrophy is present. Functional imaging studies such as single photon emission computerized tomography (SPECT) and positron emission tomography (PET) also demonstrate significant abnormalities. PET with 2-deoxy-2-fluoro-[18F]-D-glucose (FDG) usually shows reduced frontal-parietal-temporal uptake similar to patterns seen in sporadic frontotemporal dementia (FTD). PET with [18F]-fluoro-L-dopa (6FD) and [11C]-raclopride tracers reveals uptake abnormalities distinct from those seen in PD, in which the putamen is affected more than the caudate nucleus (12).

Figure 2

A) Head MRI (left panels) demonstrates cortical atrophy in frontal and temporal lobes. Positron emission tomography (PET) with 2-deoxy-2-fluoro-[18F]-D-glucose (FDG) PET (right panels) demonstrates hypometabolism in the same cortical regions. Middle panels shows co-registration of MRI and FDG PET studies.

B) Thermoregulatory sweating tests in the same patient with PPND. Shaded areas represent sweating over the anterior body surface. Distal anhidrosis is seen.



Laboratory findings

The routine serum, urine, CSF and other body fluid studies are usually negative. Clinical neurophysiological findings are summarized in [Table 1](#). Electroencephalography (EEG) findings

are normal early in the disease process and progress to diffuse slowing as the disease advances, although slowing can sometimes be seen earlier in the course of the FTDP-17 illness (13). In sporadic FTD, the slowing of background rhythms usually occurs late in the course of the illness. In individuals with the P301S mutation, EEGs demonstrate sharp waves, spikes and epileptiform discharges (14). Nerve conduction studies are normal. Electromyography may show neurogenic patterns related to lower motor neuron dysfunction (15). Evoked potential studies are usually normal. Autonomic testing may show sudomotor impairment but not orthostatic hypotension (16). There is very little information available on sleep studies in FTDP-17 kindreds. Neuropsychological evaluation is of paramount significance in determining the severity and extent of cognitive and behavioral dysfunction in this disorder. Clinical genetic testing of affected and presymptomatic individuals is commercially available for some mutations. However, the interests of at-risk family members in undergoing clinical genetic testing tend to be low (17).

Case presentation: affected individual from pallido-ponto-nigral degeneration (PPND) family characterized by parkinsonism-plus predominant phenotype

A 41-year-old right handed male with family history of PPND presented with left leg tremor. Neurological examination performed 2 years later revealed paucity of facial expressions, decrease rate of blinking, vertical supranuclear gaze palsy, axial and appendicular rigidity, left hand dystonia and stooped posture. Tremor was absent. He had mild personality changes but no dementia.

MRI showed bilateral frontotemporal atrophy (**Figure 2A**). PET using FDG revealed decreased uptake in frontotemporal region bilaterally (**Figure 2A**). Thermoregulatory sweating test showed distal extremity anhidrosis (**Figure 2B**).

Management including treatment

Currently, a curative treatment for FTDP-17 does not exist. Supportive and symptomatic treatments, however, are available. It is hoped that the development of transgenic mice will provide an opportunity to test therapeutic agents in the near future.

Etiology

Mutations in the *tau* gene cause FTDP-17. Tau is a microtubule-binding protein abundant in neurons and glia. In neurons it is predominantly expressed in axons. Tau binds to and stabilizes

microtubules and promotes microtubule assembly. The majority of the currently known mutations in coding region occur within the microtubule-binding region of tau. Most known mutations in non-coding regions affect the splicing of exon 10. The pathogenetic mechanisms in FTDP-17 are thought to be related to the altered proportion of tau isoforms or to the ability of tau to bind microtubules and to promote microtubule assembly.

Mutations in *tau* associated with FTDP-17 fall into two broad mechanistic groups. One group contains coding mutations (missense and two deletions) that, in recombinant protein studies and in transfected cell assays, have been shown to disrupt the binding of tau to microtubules. In addition, the majority of these mutations have also been shown to accelerate the aggregation of recombinant tau in the presence of polyanions. Thus, overall, these mutations are predicted both to increase the proportion of tau that is unbound to microtubules and available for aggregation and also to increase directly the tendency of the unbound tau to form filaments. The second group of tau mutations appears to cause disease by disrupting the alternative splicing of exon 10 and hence the ratio of 4R: 3R tau. These mutations comprise a mixture of coding changes, within exon 10 (N279K, delK280, L284L, N296N/H, S305S, and S305N) and also intronic mutations close to the 5' splice site of exon 10 (at positions +3, +11, +12, +13, +14 and +16). All but one of these mutations have been demonstrated to increase the splicing-in of exon 10 and hence the proportion of 4R tau. The exception is delK280 that, at least *in vitro*, results in the virtual elimination of exon 10+ mRNA (18).

Diagnostic methods

Characteristic clinical and pathological features of FTDP-17 coupled with a molecular genetic analysis of the *tau* gene are essential steps for a diagnosis.

Imaging studies (CT, MRI) can assist in establishing a diagnosis, mainly by excluding other diagnostic possibilities such as the presence of a brain tumor, abscess, multi-infarct state, or hydrocephalus.

Genetic counseling

Affected individuals should be counseled regarding the estimated probability of passing the genetic bases for their illness on to their offspring. Because FTDP-17 is an autosomal dominantly inherited condition, each offspring of an affected individual will carry a 50% risk of inheriting the abnormal gene. Some of these mutations can be detected through genetic

testing. The individual who inherits a mutation will not necessarily develop the same clinical syndrome as the parent, because penetrance may be incomplete, neurologic manifestations vary greatly even within families, or the individual might die from unrelated causes. In the case of the PPND subtype of FTDP-17, however, because penetrance is complete, virtually all individuals who inherit the mutation will become symptomatic during middle age.

At-risk individuals may sometimes choose to adopt rather than bear their own children. When faced with the option of genetic testing, some will prefer the greater certainty a genetic diagnosis may afford when planning life decisions, while others will find not knowing to be a lesser emotional burden as well as a lesser risk of being denied healthcare should their insurance carrier learn the test result. In either case the patient's choice should be respected.

Inquiring into the family history can also identify relatives who may be at-risk of having inherited the genetic basis for FTDP-17 and who thus may be presymptomatic.

References

1. Foster NL, Wilhelmsen K, Sima AA, Jones MZ, D'Amato CJ, Gilman S. Frontotemporal dementia and parkinsonism linked to chromosome 17: a consensus conference. Conference Participants. *Ann Neurol* 1997; 41:706-715
2. Wszolek ZK, Tsuboi Y, Farrer M, Uitti RJ, Hutton ML. Hereditary tauopathies and parkinsonism. *Adv Neurol* 2003; 91:153-163
3. Tsuboi Y, Baker M, Hutton ML, Uitti RJ, Rascol O, Delisle MB, Soulages X, Murrell JR, Ghetti B, Yasuda M, Komure O, Kuno S, Arima K, Sunohara N, Kobayashi T, Mizuno Y, Wszolek ZK. Clinical and genetic studies of families with the tau N279K mutation (FTDP-17). *Neurology* 2002; 59:1791-1793
4. Ghetti B, Hutton M, Wszolek ZK. Frontotemporal dementia and parkinsonism linked to chromosome 17 associated with tau gene mutations (FTDP-17). In: *Neurodegeneration. The molecular pathology of dementia and movement disorders*. Edts Dickson D, *et al*. ISN. 2003 In press.
5. Reed LA, Wszolek ZK, Hutton M. Phenotypic correlations in FTDP-17. *Neurobiol Aging* 2001; 22:89-107
6. Bird TD, Nochlin D, Poorkaj P, Cherrier M, Kaye J, Payami H, Peskind E, Lampe TH, Nemens E, Boyer PJ, Schellenberg GD. A clinical pathological comparison of three families with frontotemporal dementia and identical mutations in the tau gene (P301L). *Brain* 1999; 122:741-756
7. Bugiani O, Murrell JR, Giaccone G, Hasegawa M, Ghigo G, Tabaton M, Morbin M, Primavera A, Carella F, Solaro C, Grisoli M, Savoirdo M, Spillantini MG, Tagliavini F, Goedert M, Ghetti B. Frontotemporal dementia and corticobasal degeneration in a family with a P301S mutation in *tau*. *J Neuropathol Exp Neurol* 1999; 58:667-677
8. Cordes M, Wszolek ZK, Calne DB, Rodnitzky RL, Pfeiffer RF. Magnetic resonance imaging studies in rapidly progressive Autosomal dominant parkinsonism and dementia with pallido-ponto-nigral degeneration. *Neurodegeneration* 1992; 1:217-224
9. Murrell JR, Spillantini MG, Zolo P, Guazzelli M, Smith MJ, Hasegawa M, Redi F, Crowther RA, Pietrini P, Ghetti B, Goedert M. Tau gene mutation G389R causes a tauopathy with abundant pick body-like inclusions and axonal deposits. *J Neuropathol Exp Neurol* 1999; 58:1207-1226
10. Wszolek ZK, Pfeiffer RF, Bhatt MH, Schelper RL, Cordes M, Snow BJ, Rodnitzky RL, Wolters EC, Arwert F, Calne DB. Rapidly progressive autosomal dominant parkinsonism and dementia with pallido-ponto-nigral degeneration. *Ann Neurol* 1992; 32:312-320
11. Yasuda M, Yokoyama K, Nakayasu T, Nishimura Y, Matsui M, Yokoyama T, Miyoshi K, Tanaka C. A Japanese patient with frontotemporal dementia and parkinsonism by a tau P301S mutation. *Neurology* 2000; 55:1224-1227
12. Pal PK, Wszolek ZK, Kishore A, de la Fuente-Fernandez R, Sossi V, Uitti RJ, Dobko T, Stoessl AJ. Positron emission tomography in pallido-ponto-nigral degeneration (PPND) family (frontotemporal dementia with parkinsonism linked to chromosome 17 and point mutation in tau gene). *Parkinsonism Relat Disord* 2001; 7:81-88
13. Wszolek ZK, Lagerlund TD, Steg RF, McManis PG. Clinical neurophysiologic findings in patients with rapidly progressive familial parkinsonism and dementia with pallido-ponto-nigral degeneration. *Electroenceph Clin Neurophysiol* 1998; 107:213-222
14. Sperfeld AD, Collatz MB, Baier H, Palmbach M, Storch A, Schwarz J, Tatsch K, Reske S, Joosse M, Heutink P, Ludolph AC. FTDP-17: an early-onset phenotype with parkinsonism and epileptic seizures caused by a novel mutation. *Ann Neurol* 1999; 46:708-715
15. Lynch T, Sano M, Marder KS, Bell KL, Foster NL, Defendini RF, Sima AA, Keohane C, Nygaard TG, Fahn S, Mayeux R, Rowland LP, Wilhelmsen KC. Clinical characteristics of a family with chromosome 17-linked disinhibition-

dementia-parkinsonism-amyotrophy complex. Neurology 1994; 44:1878-1884

16. Cheshire WP, Tsuboi Y, Wszolek ZK. Physiologic assessment of autonomic dysfunction in pallidopontonigral degeneration with N279K mutation in the tau gene on chromosome 17. Auton Neurosci 2002; 102:71-77

17. McRae CA, Diem G, Yamazaki TG, Mitek A, Wszolek ZK. Interest in genetic testing in pallido-ponto-nigral degeneration (PPND): a family with frontotemporal dementia with Parkinsonism linked to chromosome 17. Eur J Neurol 2001; 8:179-183

18. Grover A, Houlden H, Baker M, Adamson J, Lewis J, Prihar G, Pickering-Brown S, Duff K, Hutton M. 5' splice site mutations in tau associated with the inherited dementia FTDP-17 affect a stem-loop structure that regulates alternative splicing of exon 10. J Biol Chem 1999; 274:15134-15143

Acknowledgements: We would like to thank all family members for their support of the research on FTDP-17. Dr. Tsuboi is supported by the Robert and Clarice Smith Fellowship in Neurodegenerative Diseases and Stroke. Dr. Wszolek is partially supported by USA NIH/NINDS/M. H. Udall Parkinson's Disease Research Center of Excellence grant.